

Does This Patient Have Aortic Regurgitation?

Niteesh K. Choudhry, MD

Edward E. Etchells, MD, MSc

CLINICAL SCENARIO

You are asked to see a 59-year-old woman with liver cirrhosis who will be undergoing sclerotherapy for esophageal varices. When she was examined by her primary care physician, she had a pulse pressure of 70 mm Hg. The primary care physician is concerned about the possibility of aortic regurgitation (AR) and asks you whether endocarditis prophylaxis is necessary for sclerotherapy. You conduct a complete physical examination and hear no early diastolic murmur in the third or fourth intercostal spaces at the left-sternal border. You feel that the patient is unlikely to have AR and that endocarditis prophylaxis is not needed. You suspect that the wide pulse pressure is a peripheral hemodynamic consequence of cirrhosis, not AR. The primary care physician, however, wonders whether the procedure should be delayed until an echocardiogram can be obtained.

WHY IS THE CLINICAL EXAMINATION IMPORTANT IN EVALUATING FOR AR?

Aortic regurgitation is a potentially serious cardiac abnormality that may be caused by important underlying disorders. Patients with AR require careful clinical monitoring to identify the optimal time for surgical intervention. Asymptomatic patients with severe AR may benefit from vasodilator therapy.¹ Endocarditis prophylaxis may be indicated for patients with AR who are undergoing various procedures.²

The use of noninvasive cardiac testing, such as echocardiography, has in-

Objective To review evidence as to the precision and accuracy of clinical examination for aortic regurgitation (AR).

Methods We conducted a structured MEDLINE search of English-language articles (January 1966-July 1997), manually reviewed all reference lists of potentially relevant articles, and contacted authors of relevant studies for additional information. Each study (n = 16) was independently reviewed by both authors and graded for methodological quality.

Results Most studies assessed cardiologists as examiners. Cardiologists' precision for detecting diastolic murmurs was moderate using audiotapes ($\kappa = 0.51$) and was good in the clinical setting (simple agreement, 94%). The most useful finding for ruling in AR is the presence of an early diastolic murmur (positive likelihood ratio [LR], 8.8-32.0 [95% confidence interval {CI}, 2.8-32 to 16-63] for detecting mild or greater AR and 4.0-8.3 [95% CI, 2.5-6.9 to 6.2-11] for detecting moderate or greater AR) (2 grade A studies). The most useful finding for ruling out AR is the absence of early diastolic murmur (negative LR, 0.2-0.3 [95% CI, 0.1-0.3 to 0.2-0.4] for mild or greater AR and 0.1 [95% CI, 0.0-0.3] for moderate or greater AR) (2 grade A studies). Except for a test evaluating the response to transient arterial occlusion (positive LR, 8.4 [95% CI, 1.3-81.0]; negative LR, 0.3 [95% CI, 0.1-0.8]), most signs display poor sensitivity and specificity for AR.

Conclusion Clinical examination by cardiologists is accurate for detecting AR, but not enough is known about the examinations of less-expert clinicians.

JAMA. 1999;281:2231-2238

www.jama.com

creased in recent years. It is estimated that 2% of the general population undergoes noninvasive cardiac diagnostic evaluation annually.³ If a careful clinical examination can exclude the presence of AR, then there would be no need to proceed with further cardiac evaluation.

Anatomical and Physiological Origins of Diastolic Murmurs

The cardinal manifestation of AR is a diastolic murmur. Diastolic murmurs are important indicators of structural cardiac abnormalities or pathological states of increased flow (TABLE 1). As discussed in a previous article in this series,⁴ heart murmurs are produced when turbulent blood flow causes prolonged auditory vibrations of cardiac structures. The intensity of the murmur depends on many factors, includ-

ing blood viscosity, blood flow velocity and turbulence, the distance between the vibrations and the stethoscope, the angle at which the vibrations meet the stethoscope, the transmission qualities of the tissue between the vibration and the stethoscope, and the auditory capabilities of the examiner.⁵

How to Examine for AR

A complete clinical history and physical examination are essential in the

Author Affiliations: Division of General Internal Medicine and Clinical Epidemiology, Department of Medicine, University of Toronto and the University Health Network, Toronto, Ontario.

Corresponding Author: Edward E. Etchells, MD, MSc, University Health Network, 200 Elizabeth St, eng-248, Toronto, Ontario, Canada M5G 2C4 (e-mail: eetchells@torhosp.toronto.on.ca).

The Rational Clinical Examination Section Editors: David L. Simel, MD, MHS, Durham Veterans Affairs Medical Center and Duke University Medical Center, Durham, NC; Drummond Rennie, MD, Deputy Editor (West), JAMA.

evaluation of patients with a diastolic murmur. A diastolic murmur in a patient with renal failure and volume overload will have different significance than a diastolic murmur in a patient with a history of rheumatic fever and atrial fibrillation.

The examiner's ability to detect a diastolic murmur can be undermined by environmental factors such as noisy rooms, examiner factors such as fatigue or haste, and patient factors such as dyspnea or tachycardia.⁶ If examining conditions are not optimal, the examination should be repeated when conditions improve.

Table 1. Selected Causes of Diastolic Murmurs

Abnormal cardiac structure
Aortic regurgitation
Mitral stenosis
Pulmonic regurgitation
Tricuspid stenosis
Atrial myxoma
Ventricular septal defect*
Atrial septal defect*
Mitral regurgitation*
Normal cardiac structure, increased flow
Renal failure with volume overload
Thyrotoxicosis
Anemia
Sepsis

*Diastolic murmurs are caused by abnormally increased diastolic flow across the mitral or tricuspid valves.

The precision and accuracy of many individual components of the examination for AR, including all of the cardiac history and most of the physical examination, have not been adequately evaluated. This article will focus on aspects of the cardiac physical examination that have been sufficiently assessed for precision or accuracy.

Cardiac Auscultation

During routine auscultation, the examiner attempts to detect a diastolic murmur. Diastole is the period that begins with the closure of the aortic and pulmonic valves (second heart sound [S_2]) and ends with the closure of the mitral and tricuspid valves (first heart sound [S_1]). A common maneuver used to identify diastole is to palpate the carotid artery pulse during auscultation; S_1 is synchronous with the carotid artery pulsation while S_2 follows the pulse. A diastolic murmur is a diastolic sound longer than a heart sound. Examiners should describe the grade, location of maximal intensity (FIGURE 1), timing (FIGURE 2), duration, pitch, and radiation of the murmur.

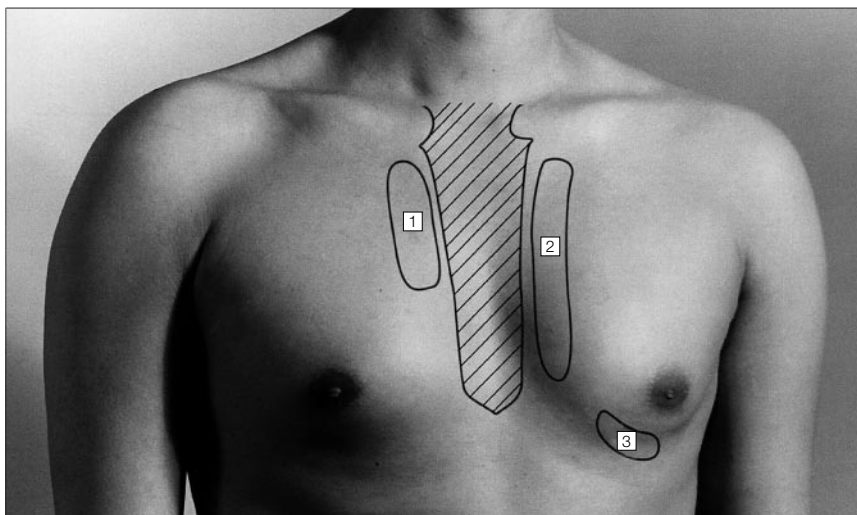
The Levine grading system,⁷ with slight modifications,⁸ was developed for

systolic murmurs but may also be used to describe diastolic murmurs. A grade 1 murmur is not heard immediately on auscultation, but is heard after the examiner focuses for a few seconds. Grade 2 murmurs are heard immediately on auscultation but are softer than the loud grade 3. Grade 4 murmurs are associated with a palpable precordial vibration called a *thrill*. (Grade 5 and 6 murmurs are also associated with a thrill. A grade 5 murmur is audible when only 1 edge of the stethoscope is on the chest, and a grade 6 murmur is audible with the entire stethoscope lifted off the chest.)

The typical murmur of AR is an early diastolic, decrescendo blowing sound (Figure 2), which may be accentuated with the patient sitting upright and leaning forward.⁹ In some cases, S_2 can be obscured by the murmur. Most AR murmurs are high pitched and are best heard with the diaphragm of the stethoscope placed firmly on the chest wall. Some AR murmurs are low pitched and are better heard with the bell of the stethoscope placed lightly on the chest wall. For example, the AR murmur associated with endocarditis and a fenestrated aortic valve can be low pitched.

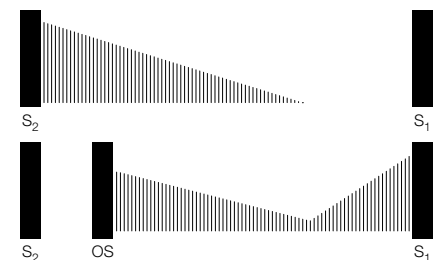
The examiner should apply the stethoscope to the chest wall in the third or

Figure 1. Typical Location of Abnormal Diastolic Murmurs



There are 3 important areas to auscultate for diastolic murmurs. Area 1 is the second and third intercostal spaces at the right-sternal border. Area 2 is the second and fourth intercostal spaces at the left-sternal border. Aortic regurgitation murmurs may be heard in both areas 1 and 2. If the murmur is loudest in area 1, then the underlying cause of aortic regurgitation may be an ascending aortic aneurysm or aortic dissection. Pulmonic regurgitation murmurs are loudest in the superior part of area 2, and may radiate downward. The murmur of mitral stenosis and the Flint murmur of aortic regurgitation are best heard at the apex (area 3).

Figure 2. Selected Features of Diastolic Murmurs



Diastolic murmurs are classified based on the time of onset of the murmur.¹⁵ An early diastolic murmur begins with the second heart sound (S_2). Top, Early diastolic murmurs typically decrease in intensity (decrescendo) and disappear before the first heart sound (S_1). In some cases, an early diastolic murmur can continue through diastole. Bottom, A mid-diastolic murmur begins clearly after S_2 (in mitral stenosis, classically after an opening snap [OS]). A late diastolic (or presystolic) murmur begins in the interval immediately before S_1 . In mitral stenosis, the mid-diastolic murmur may merge with the late systolic murmur.

fourth intercostal space at the left sternal border and listen while the patient stops his/her breath at end of expiration. The patient should not hold his/her breath because he/she may inadvertently do a Valsalva maneuver. If the murmur is louder at the second to third right intercostal space, the underlying cause of AR may be an ascending aortic aneurysm or aortic dissection.¹⁰

Aortic regurgitation also may be associated with a systolic murmur,¹¹ which results from the flow of an abnormally large volume of blood through a nonstenotic aortic valve or a bicuspid aortic valve. The murmur is an early peaking, crescendo-decrescendo systolic sound that is best heard with the diaphragm of the stethoscope applied to the second-right intercostal space.

The Flint murmur is a low-pitched late-diastolic apical murmur, which is associated with AR. The murmur is likely produced when the regurgitant jet of blood collides with the left ventricular endocardium.¹² The murmur may have a mid-diastolic component, but the original description by Flint referred only to "presystolic blubbling."¹³ It is best heard with the patient in the left-lateral decubitus position using the bell of the stethoscope. Differentiating the Flint murmur from the murmur of mitral stenosis can be difficult. The murmur of mitral stenosis is primarily mid-diastolic (possibly with a late diastolic component) and may be associated with an opening snap (OS) and a loud S_1 (Figure 2).¹⁴

The typical murmur of pulmonic regurgitation (PR) is an early diastolic decrescendo murmur heard best in the second-left intercostal space at the sternal border. The murmur may radiate to the third- and fourth-left intercostal spaces, and may increase during quiet inspiration. If there is splitting of S_2 , the astute examiner may note that the murmur begins after the pulmonic valve component (P_2) of S_2 rather than the aortic component. The murmur of PR may be lower pitched than the murmur of AR, unless pulmonary hypertension is present. A right-sided Flint murmur can be heard, particularly in patients with pulmonary hypertension.

Mitral stenosis is associated with a mid-diastolic decrescendo low-frequency rumble, which, if the patient is in sinus rhythm, may be followed by late-diastolic (presystolic) crescendo that ends with the mitral component of S_1 (Figure 2). It is best heard using the bell of the stethoscope placed at the apex soon after moving the patient into the left-lateral decubitus position. This will both bring the left ventricle closer to the chest wall and serve as a form of exercise, which will increase flow across the mitral valve and, therefore, increase the intensity of the murmur.¹⁰ The murmur of mitral stenosis may be inaudible in patients with low cardiac output.

The S_1 may be increased in intensity in mitral stenosis.¹⁴ A normal S_1 is best appreciated near the apex where it should be louder than S_2 . The S_1 is normally softer than S_2 in the second-right and second-left intercostal spaces adjacent to the sternum. If S_1 is as loud as or louder than the S_2 in these areas, then the S_1 is increased in intensity.

An OS is a high-frequency early diastolic sound that is associated with the opening of a stenotic mitral valve. It occurs 50 to 100 milliseconds after the aortic valve component (A_2) of S_2 and is best heard in the area from the left sternal border to the apex. Much like the murmur of mitral stenosis, it may be accentuated by listening to the patient in the left-lateral decubitus position shortly after the patient has performed exercise. The A_2 -OS interval shortens with increasing severity of mitral stenosis. The OS may be absent in the case of a heavily calcified immobile mitral valve. It is often difficult to differentiate an OS from the P_2 of S_2 . The OS usually decreases in intensity with inspiration and S_2 -OS interval widens on standing. Conversely, P_2 becomes louder with inspiration and the A_2 - P_2 interval remains the same or narrows with standing.¹⁴ Additionally, P_2 is not expected to be heard at the apex unless the patient has pulmonary hypertension.

Maneuvers

Selective use of maneuvers can enhance the detection and interpretation

of diastolic murmurs. There is no point in doing maneuvers if a loud AR murmur has been detected during routine auscultation. However, if the clinician is unsure about the presence of a faint diastolic murmur, then a maneuver that increases murmur intensity may clarify the situation. If the clinician has a heightened suspicion for AR (eg, after hearing an aortic ejection sound), or if examining conditions are not optimal, then a maneuver to augment murmur intensity might bring out an otherwise inaudible murmur. Finally, if the clinician is unsure whether a murmur represents PR or AR, then these maneuvers may help distinguish between the 2. In this latter situation, the clinician should listen where the murmur is just barely audible, so that it is easy to detect a decrease or increase in murmur intensity during the maneuver.

Quiet inspiration increases venous return and is intended to augment right-sided heart murmurs such as PR. To determine the effect of inspiration on the intensity of the murmur, the examiner should listen during quiet inspiration rather than asking the patient to breathe deeply, as the murmur may be obscured by breath sounds.

Transient arterial occlusion primarily increases systemic arterial resistance that results in an intensification of left-sided regurgitant lesions such as AR and may help distinguish the murmur from that of PR. To perform this maneuver, sphygmomanometers are placed around both of the patient's arms and are inflated to 20 to 40 mm Hg above the previously recorded systolic blood pressure. Any changes in murmur intensity are noted 20 seconds after cuff inflation.¹⁶

Peripheral Hemodynamic Signs

There are a variety of peripheral hemodynamic signs traditionally associated with AR. Some of these signs have been adequately evaluated, including de Musset head bobbing sign,¹⁷ a wide pulse pressure,¹⁸ the brachial-popliteal pulse gradient (Hill sign¹⁹), Duroziez femoral murmur,¹⁷ the femoral pistol shot murmur,¹⁴ and Corrigan water hammer pulse.²⁰ The de Musset head bob-

bing sign consists of a forward shaking of the head with every heartbeat; it is best observed in patients who are sitting.¹⁷

Pulse pressure refers to the difference between systolic and diastolic blood pressures. A widened pulse pressure may be defined as greater than 50 mm Hg.²¹ Other definitions include a pulse pressure greater than 50% of the systolic pressure.¹⁸ Determination of the blood pressure has been described in another article in this series.²²

The brachial-popliteal pulse gradient (Hill sign) can be defined as a systolic blood pressure in the lower extremities that is at least 20 mm Hg higher than that in the arms.²¹ To determine a popliteal blood pressure, an appropriately sized blood pressure cuff should be placed on the patient's thigh¹⁴ with the artery marker over the popliteal artery; the cuff should be inflated and the systolic pressure can then be determined in the popliteal fossa either by palpation, as judged by the point where the pulse reappears as the cuff is deflated, or by auscultation, listening for Korotkoff sounds to appear. Both the brachial and popliteal blood pressures should be measured while the patient is supine. The average of repeated readings should be used, especially in patients with irregular heart rates, such as atrial fibrillation.

Duroziez double intermittent femoral bruit is elicited by first gently compressing the femoral artery with the diaphragm of the stethoscope. This will yield a systolic bruit in all patients. As increasing pressure is applied to the diaphragm, an early diastolic bruit will become audible in patients with AR. While listening to the diastolic bruit, the stethoscope should then be tilted such that the distal rim (closest to the patient's feet) is compressing the femoral artery. If the bruit becomes louder with this maneuver then the diastolic bruit is due to the retrograde flow of blood toward the heart in AR. The stethoscope should then be tilted such that the proximal rim (closest to the patient's head) is compressing the femoral artery. If the diastolic bruit becomes softer, this can be taken as supportive evidence of the presence of

retrograde blood flow. If, however, the bruit becomes louder with proximal pressure (and softer with distal pressure), then this sign should not be used as evidence of AR but may indicate the presence of a high-flow state such as renal failure with volume overload.²³

Femoral pistol shot sounds are elicited by auscultating with the diaphragm of the stethoscope over the femoral arteries. A high-pitched pistol shot sound may be heard in AR. Corrigan water hammer pulse refers to an increased volume and rate of rise of the radial pulse when the wrist is elevated perpendicular to the body of a supine patient. The radial pulse should first be assessed while the patient is lying supine with his/her arms resting at the sides. Sufficient pressure should be applied to obliterate the pulse. While maintaining this pressure, the patient's arm should be elevated such that it is perpendicular to the plane of the body. In AR, the pulse will become palpable despite applying an equivalent amount of pressure as when the arm was at the patient's side.

Other peripheral hemodynamic signs, such as Mayne sign (a decrease in diastolic blood pressure of 15 mm Hg when the arm is held above the head compared with when the arm is held at the level of the heart),²⁴ Quinke capillary pulsation, Muller pulsatile uvula, and Rosenbach liver pulsation, have not been adequately evaluated for precision or accuracy.

METHODS

To identify articles pertaining to the precision and accuracy of the physical examination for AR, we used standard methods for conducting research overviews.²⁵ Our data collection strategy involved 3 steps and was deliberately broad to reduce the possibility of overlooking important articles. First, we searched MEDLINE for English-language articles from 1966 through July 1997 using a structured search strategy (available on request from the authors). Second, we manually reviewed potentially relevant articles and their reference lists. Third, we contacted the authors of rel-

evant studies for additional information. Studies were excluded if they were review articles, involved patients younger than 18 years, were small (ie, <20 participants), involved prosthetic heart valves, if no clinical examination was performed or reported, or if there was no acceptable reference standard (Doppler echocardiography or cardiac catheterization).

Studies were independently reviewed for methodological quality by the 2 authors and disagreements were resolved by consensus. Quality grades were assigned using published guidelines.²⁶ Grade A studies involve the independent comparison of a sign or symptom with a reference standard of diagnosis among a large number of consecutive patients suspected of having the target condition. Grade B studies meet the criteria for grade A studies but have a small number of patients. Grade C studies involve nonconsecutive patients, patients who are known to have the target condition and healthy individuals, nonindependent comparisons between the sign or symptom and the reference standard, or nonindependent comparison with a reference standard of uncertain validity. Grade C studies tend to overestimate the accuracy of the sign or symptom.

We recreated contingency tables for all studies and determined the likelihood ratios (LRs) for the cardiac disease of interest.^{27,28} When a cell from the table included a value of zero, confidence intervals (CIs) for the LRs were estimated using an iterative approach. We also sought information on the examination for other causes of diastolic murmurs, such as mitral stenosis or PR. Unfortunately, we found few studies of sufficient methodological quality for these conditions. This relative lack of information implies that methodologically sound studies are needed, but does not imply that the clinical examination for these conditions is imprecise, inaccurate, or unimportant.

Precision of the Examination Related to Diastolic Murmurs

Precision refers to agreement regarding a particular clinical finding between dif-

ferent physicians (interobserver) or between multiple assessments by the same physician (intraobserver). The precision of the clinical examination for diastolic murmurs has been evaluated in usual clinical situations by auscultating patients^{29,30} or in controlled nonclinical circumstances by listening to recorded audiotapes (TABLE 2).³¹

There have been 4 studies that address the interobserver precision of cardiac auscultation to detect diastolic murmurs (Table 2). While simple agreement is high in these studies, the 1 study for which it was possible to calculate agreement adjusted for chance (κ) showed only moderate agreement. The experience of observers likely affects precision. The 1 study²⁹ that compared cardiologists with noncardiologists found a higher simple agreement for cardiologists.

The interobserver agreement between examiners on the intensity of heart sounds is excellent (92%).³⁰ In this study, examiners progressively inserted 0.5-mm-thick paper disks between the patient's chest and the stethoscope. The total thickness of the disks was used as a measure of heart sound intensity. Murmur intensity was also assessed using this technique (Table 2).

The Bottom Line for Precision

The interobserver precision of cardiologists examining for any diastolic murmur is moderate using audiotapes ($\kappa = 0.51$) and good in the clinical setting (simple agreement, 94%). Noncardiologists may be less precise than cardiologists. The precision of examining for the intensity of murmurs and heart sounds using a standardized series of paper disks to assess intensity is good (simple agreement, 92%-96%).

Accuracy of the Examination for AR

We consider Doppler echocardiography and cardiac catheterization to be acceptable reference standards for AR (TABLE 3). In 1 study, the reference standard was open-heart surgery. Some studies explicitly graded the severity of AR detected by the reference standard (for example, on the basis of the abso-

Table 2. Interobserver Reliability (Precision) for Detecting Diastolic Murmurs*

Finding	Type of Examiner	No. of Examiners	No. of Patients	κ	Simple Agreement, %
Murmur absent vs present	Cardiologists (tapes) ³¹	5	100	0.51	79
	Cardiologists ²⁹	2	32	...	94
	Noncardiologists ²⁹	3	32	...	78
Intensity of murmur	Not stated ^{30†}	5	25	...	92

*Ellipses indicate data not available.

†Examiners used paper disks, 0.5 mm in thickness, that were progressively inserted between the chest wall and the stethoscope until the murmur became inaudible. The total thickness of the disks used was used as the measure of intensity. For example, if a murmur was inaudible after inserting 3 disks, then this was a 1.5-mm murmur.

lute height of the regurgitant jet or the ratio of the height of the jet to the height of the left ventricular outflow tract on Doppler echocardiography), which allowed us to calculate LRs for detecting both mild (or worse) and moderate (or worse) AR.

Cardiologists conducted the clinical examinations in most studies. Too few studies, using few patients, allow for reasonable estimates of the accuracy of noncardiologists, although noncardiologists are likely less adept at detecting the diastolic murmur of AR. Approximately 20% of residents and medical students correctly identified the murmur of AR on high-fidelity digitized audiotapes,³² while 46% of internal medicine residents correctly identified an AR murmur using a patient simulator.³³

The best-studied physical finding is the typical early diastolic murmur of AR.³⁴⁻⁴⁷ If an examiner does not hear a typical AR murmur then the likelihood that the patient has moderate or greater AR is significantly reduced (negative LR, 0.1 for grade A studies); the likelihood of mild or greater AR is also significantly reduced (negative LR, 0.2-0.3 for grade A studies).^{34,35}

If an examiner hears the typical AR murmur, the likelihood that the patient has moderate or greater AR is increased (positive LR, 4.0-8.3 for grade A studies); the likelihood of mild or greater AR is also significantly increased (positive LR, 8.8-32.0 for grade A studies).^{34,35}

The intensity of the murmur correlates with the severity of echocardiographic AR. Desjardins et al⁴⁸ studied 40 patients with echocardiographic AR, including 17 with severe AR. A grade 3 diastolic murmur had an LR of 4.5

(95% CI, 1.6-14.0) for distinguishing severe AR from less severe AR, while a grade 2 murmur had an LR of 1.1 (95% CI, 0.5-2.4), a grade 1 murmur had an LR of 0.0 (95% CI, 0.0-0.9), and absence of a diastolic murmur had an LR of 0.0 (95% CI, 0.0-1.1).⁴⁸

Two grade C studies of the Flint murmur and some peripheral hemodynamic findings are reported in Table 3. Grade C studies tend to overestimate diagnostic test accuracy. Despite this tendency, 1 study found that absence of a Flint murmur did not rule out AR (negative LR, 0.5-0.8).⁴⁹ Another study of patients with mild-to-severe AR only found that a wide pulse pressure or peripheral hemodynamic sign (Duroziez bruit, femoral pistol shots, and Corrigan pulses) was not helpful for distinguishing mild AR from moderate or severe AR.²¹

One small study (grade C) evaluated peripheral hemodynamic signs in patients exclusively with proven AR of varying severity defined by aortography or surgery. These studies provide an estimate of the sensitivity of the peripheral hemodynamic signs. The de Musset head bobbing sign was seen in only 1 of 20 patients (sensitivity, 5%) and Duroziez femoral bruit was observed in 8 of 12 patients (sensitivity, 67%).¹⁷

THE BOTTOM LINE FOR AR

When a cardiologist hears the typical murmur of AR, the likelihood of mild or greater AR is increased significantly (2 grade A studies). The absence of a typical diastolic murmur significantly reduces the likelihood of AR (2 grade A studies). Noncardiologists may be less proficient than cardiologists at detecting the murmur of AR.

Mitral Stenosis and PR

In 1 grade A study of 529 unselected nursing home residents (31 with mitral stenosis), a cardiologist detected a mid-diastolic murmur in all cases of mitral stenosis, with no false-positive or -negative examinations (W. A. Aronow, MD, written communication, 1997).⁵⁰ Only 1 patient had an audible OS.

Noncardiologists may be less proficient at detecting the physical findings of mitral stenosis. Less than 10%

of residents and medical students correctly identified a mid-diastolic murmur of mitral stenosis on a high-fidelity digitized audiotape,³² while 43% of medical residents identified a mid-diastolic murmur of mitral stenosis using a patient simulator. In the latter study, only 21% identified the OS of mitral stenosis.³³

The only evaluated element of the clinical examination for PR is the presence of a typical diastolic decrescendo

murmur best audible in the second intercostal space at the left-upper sternal border, which may increase in intensity with quiet inspiration. All studies used cardiologists as examiners and were of poor methodologic quality (grade C).

When a cardiologist hears the murmur of PR, the likelihood of PR increases (positive LR, 17 in both studies), but absence of a PR murmur was not helpful for ruling out PR (LR, 0.9 in both studies).^{37,43}

Table 3. Accuracy of the Physical Examination for Detecting Aortic Regurgitation*

Study	Patient Population	Reference Standard	No. of Patients With AR	Positive Likelihood Ratio (95% CI)†	Negative Likelihood Ratio (95% CI)‡	Quality Grade
Typical Murmur With Severity of AR Specified						
Aronow and Kronzon, ³⁴ 1989	Elderly patients	Echocardiography (n = 450)				A
		Mild or greater AR	131	32 (16-63)	0.2 (0.1-0.3)	
		Moderate or greater AR	74	8.3 (6.2-11)	0.1 (0.0-0.2)	
Grayburn et al, ³⁵ 1986	Referred for catheterization	Catheterization (n = 106)				A
		Mild or greater AR	82	8.8 (2.8-32)	0.3 (0.2-0.4)	
		Moderate or greater AR	57	4.0 (2.5-6.9)	0.1 (0.1-0.3)	
Roldan et al, ³⁶ 1996	Asymptomatic connective tissue disease and controls	Echocardiography (n = 143)				C
		Mild or greater AR	10	80 (14-470)	0.4 (0.2-0.7)	
		Moderate or greater AR	5	69 (18-270)	0.0 (0.0-0.6)	
Rahko, ³⁷ 1989	Referred for echocardiogram	Echocardiography (n = 403)				C
		Mild or greater AR	134	27 (13-60)	0.4 (0.3-0.5)	
		Moderate or greater AR	82	12 (8.1-19)	0.2 (0.1-0.3)	
Cohn et al, ³⁸ 1967	Mitral valve repair	Open-heart surgery (n = 156)				C
		Mild or greater AR	50	5.2 (3.3-8.4)	0.3 (0.2-0.4)	
		Moderate or greater AR	37	3.9 (2.6-5.7)	0.2 (0.1-0.4)	
Meyers et al, ³⁹ 1982	Referred for aortography	Catheterization (n = 75)				C
		Mild or greater AR	66	3.3 (1.3-12)	0.4 (0.2-0.7)	
		Moderate or greater AR	39	1.6 (1.2-2.4)	0.4 (0.2-0.7)	
Dittmann et al, ⁴⁰ 1987	Valvular heart disease	Catheterization (n = 55)				C§
		Mild or greater AR	42	16 (2.1-155)	0.4 (0.3-0.6)	
		Severe AR	19	3.6 (2.1-6.6)	0.1 (0.0-0.4)	
Meyers et al, ⁴¹ 1985	Valvular heart disease	Catheterization (n = 20)				C
		Mild or greater AR	11	9.8 (1.3-96)	0.5 (0.2-0.9)	
		Moderate or greater AR	3	5.7 (1.4-14)	0.0 (0.0-0.9)	
Linhart, ⁴² 1971	Mitral stenosis	Catheterization (n = 28)				C
		Mild or greater AR	11	6.2 (1.9-23)	0.3 (0.1-0.7)	
		Moderate or greater AR	7	7.0 (2.5-20)	0.0 (0.0-1.3)	
Typical Murmur Without AR Severity Specified (May Include Trivial AR)						
Come et al, ⁴³ 1986	Mitral valve prolapse, plus patients with systolic flow murmurs	Echocardiography (n = 165)	7	90 (8-982)	0.7 (0.4-0.9)	C
Nienaber et al, ⁴⁴ 1993	Clinically suspected aortic dissection	Echocardiography (n = 110)	32	33 (9.4-120)	0.2 (0.1-0.3)	C
Ward et al, ⁴⁵ 1977	Clinically suspected aortic dissection	Catheterization (n = 65)	49	13 (2.9-75)	0.2 (0.1-0.3)	C
Esper, ⁴⁶ 1982	AR and other heart disease	Echocardiography (n = 43)	24	12 (2.4-67)	0.4 (0.3-0.7)	C
Saal et al, ⁴⁷ 1985	Mitral stenosis	Catheterization (n = 45)	35	8.0 (1.9-45)	0.2 (0.1-0.4)	C

The Bottom Line for Mitral Stenosis and PR

Presence of a mid-diastolic murmur significantly increases the likelihood of mitral stenosis, while absence of a mid-diastolic murmur significantly reduces the likelihood of mitral stenosis (1 grade A study). When a cardiologist hears a typical PR murmur, the likelihood of PR increases significantly. Absence of a typical murmur does not alter the likelihood of PR (2 grade C studies). Non-cardiologists may be less proficient at detecting the mid-diastolic murmur of mitral stenosis.

Diastolic Murmurs in Patients With Renal Failure

Diastolic murmurs due to abnormal flow states, rather than abnormal cardiac structure, may be associated with a variety of conditions. Renal failure with volume overload is the only abnormal flow state associated with diastolic murmurs that has been evaluated.

Up to 9% of patients with end-stage renal disease have diastolic murmurs, particularly when these patients also have

volume overload, anemia, and hypertension.⁵¹ These murmurs typically disappear after the treatment of volume overload, as was demonstrated in 2 small studies (grade C).^{51,52} These murmurs are probably due to transient pulmonary hypertension and dilation of the pulmonary artery root, leading to PR.⁵²

The Bottom Line for Diastolic Murmurs in Patients With Renal Failure

Although there is an insufficient amount of data on which to make rigorous recommendations, if an early diastolic murmur is heard in a dialysis patient with volume overload, the patient should be reexamined after treatment because the murmur may disappear.

When to Examine for AR

There are no evaluative data on which to base a recommendation regarding when to examine for AR. Undetected AR may be common in elderly persons: 13% (n = 552) of asymptomatic elderly Finnish persons had moderate or severe echocardiographic AR.⁵³ Unfortunately, that

study does not indicate how many of these patients had audible diastolic murmurs. Audible diastolic murmurs may be relatively uncommon findings in asymptomatic persons. In 1 study only 1% (n = 103) of elderly asymptomatic nursing home residents had an audible diastolic murmur.⁵⁴

Despite the lack of evaluative data, we think that a prudent clinician will examine for AR in most clinical settings. Aortic regurgitation is a serious cardiac abnormality, which may be caused by underlying disorders and may be asymptomatic. The clinician's suspicion for AR may be heightened by evidence of systemic disease, such as ankylosing spondylitis, a peripheral hemodynamic finding (although these are by no means indicative of underlying AR), or an abnormality detected during routine auscultation (such as an aortic ejection sound). Other findings may suggest different cardiac abnormalities associated with diastolic murmurs, such as evidence of pulmonary hypertension (for PR), a wide-fixed split S₂ (for atrial-septal defect), or a holo-

Table 3. Accuracy of the Physical Examination for Detecting Aortic Regurgitation* (cont)

Study	Patient Population	Reference Standard	No. of Patients With AR	Positive Likelihood Ratio (95% CI)†	Negative Likelihood Ratio (95% CI)‡	Quality Grade
Maneuver						
With transient arterial occlusion murmur increases in intensity ¹⁶	Patients with AR, mitral stenosis, and pulmonic regurgitation	Catheterization or echocardiography (n = 16)	10	8.4 (1.3-81)	0.3 (0.1-0.8)	C
Associated Physical Findings						
Flint murmur ⁴⁹	Isolated AR and controls	Echocardiography (n = 36)				C
		Mild or greater AR	28	4 (0.5-40)	0.8 (0.6-1.3)	
		Moderate or greater AR	13	25 (2.8-243)	0.5 (0.2-0.7)	
Any systolic murmur ⁴⁹	Isolated AR and controls	Echocardiography (n = 36)				C
		Mild or greater AR	28	1.3 (0.9-2.7)	0.5 (0.2-1.6)	
		Moderate or greater AR	13	1.5 (1.0-2.1)	0.0 (0.0-1.0)	
Popliteal-brachial gradient >20 mm Hg ²¹	Mild to severe AR	Catheterization (n = 33)				C
		Moderate or greater AR	28	8.2 (1.5-78)	0.2 (0.1-0.5)	
Peripheral hemodynamic signs ²¹ ¶	Mild to severe AR	Catheterization (n = 34)				C
		Moderate or greater AR	28	2.1 (0.3-22)	0.8 (0.7-1.7)	
Pulse pressure >50 mm Hg ²¹	Mild to severe AR	Catheterization (n = 33)				C
		Moderate or greater AR	28	1.0 (0.7-2.2)	0.9 (0.2-5.5)	

*AR indicates aortic regurgitation; CI, confidence interval.

†The applicable likelihood ratio when the finding is present.

‡The applicable likelihood ratio when the finding is absent.

§Grade B study except catheterization results not interpreted independently of clinical findings.

¶Grade B study except echocardiogram not interpreted independently of clinical findings.

||Included Duroziez bruit, femoral pistol shots, and Corrigan pulses.

systolic apical murmur (for mitral regurgitation).

Recommendations for Further Research

Most studies used cardiologists to conduct clinical examinations. There are some data that suggest that noncardiologists may be less accurate than cardiologists, so studies evaluating techniques to improve the skills of noncardiologists are needed. There are also no studies defining the optimal examination technique for detecting the AR murmur.

SCENARIO RESOLUTION

Your patient, who will be undergoing sclerotherapy for esophageal varices, has a wide pulse pressure but no typical early diastolic murmur. The likelihood of mild or moderate AR is significantly reduced by the absence of a typical early diastolic murmur (negative LR, 0.1-0.3; 2 grade A studies). You perform transient arterial occlusion and no diastolic murmur appears, which enhances your confidence (negative LR, 0.3). You are confident in your assessment because it was conducted in a

quiet room with a comfortable and cooperative patient. You can advise the primary care physician that AR is unlikely and echocardiography is not necessary.

Funding/Support: This work was funded in part by grant 98-01R from Physicians Services Incorporated Foundation.

Disclaimer: The views expressed in this article are those of the authors and do not reflect those of any sponsoring or supporting agency.

Acknowledgment: We thank Eugene Oddone, MD, MHS, for his helpful comments on earlier drafts of this article, and W. S. Aronow, MD, and C. A. Nienaber, MD, for providing additional data and methodological information about their studies.

REFERENCES

- Scognamiglio R, Rahimtoola SH, Fasoli G, Nistri S, Volta SD. Nifedipine in asymptomatic patients with severe aortic regurgitation and normal left ventricular function. *N Engl J Med.* 1994;331:689-694.
- Dajani AS, Taubert KA, Wilson W, et al. Prevention of bacterial endocarditis. *JAMA.* 1997;277:1794-1801.
- Ballard DJ, Khadeira BK, Tajik AJ, Seward JB, Weber VP, Melton LJ. Population-based study of echocardiography. *Int J Technol Assess Health Care.* 1989;5:249-261.
- Etchells E, Bell C, Robb K. Does this patient have an abnormal systolic murmur? *JAMA.* 1997;277:564-571.
- Rushmer RF, Sparkman DR, Polley RFL, et al. Variability in detection and interpretation of heart murmurs. *AJDC.* 1952;83:740-754.
- Feinstein AR, Di Massa R. The unheard diastolic murmur in acute rheumatic fever. *N Engl J Med.* 1959;260:1331-1333.
- Freeman AR, Levine SA. The clinical significance of the systolic murmur: a study of 1000 consecutive cases. *Ann Intern Med.* 1933;6:1371-1385.
- Constant J, Lippschultz EJ. Diagramming and grading heart sounds and murmurs. *Am Heart J.* 1965;70:322-326.
- Constant J. *Bedside Cardiology.* 3rd ed. Boston, Mass: Little Brown & Co Inc; 1985.
- Harvey WP. Cardiac pearls. *Dis Mon.* 1994;40:43-113.
- Shaver JA. Cardiac auscultation. *Curr Probl Cardiol.* 1995;20:445-530.
- Landzberg JS, Pflugfelder PW, Cassidy MM, Schiller NB, Higgins CB, Chaitlin MD. Etiology of the Austin Flint murmur. *J Am Coll Cardiol.* 1992;20:408-413.
- Flint A. On cardiac murmurs. *Am J Med Sci.* 1862;44:29-54.
- Sapira JD. *The Art and Science of Bedside Diagnosis.* Baltimore, Md: Urban & Schwarzenberg; 1990.
- Soffer A, Feinstein A, Rosener S, et al. Glossary of cardiologic terms related to physical diagnosis and history. *Am J Cardiol.* 1967;20:285-286.
- Lembo NJ, Dell'Italia LJ, Crawford MH, O'Rourke RA. Diagnosis of left-sided regurgitant murmurs by transient arterial occlusion: a new maneuver using blood pressure cuffs. *Ann Intern Med.* 1986;105:368-370.
- Sapira JD. Quincke, de Musset, Duroziez, and Hill. *South Med J.* 1981;74:459-467.
- Hegglin R, Scheu H, Rothlin M. Aortic insufficiency. *Circulation.* 1968;37(suppl V):V77-V92.
- Hill L. The measurement of systolic blood pressure in man. *Heart.* 1909;1:73-82.
- Warnes CA, Harris PC, Fritts HW. Effect of elevating the wrist on the radial pulse in aortic regurgitation. *Am J Cardiol.* 1983;51:1551-1553.
- Frank MJ, Casanegra P, Migliori AJ, Levinson GE. The clinical evaluation of aortic regurgitation. *Arch Intern Med.* 1965;116:357-365.
- Reeves RA. Does this patient have hypertension? *JAMA.* 1995;273:1211-1218.
- Blumgart HL, Ernstene AC. Two mechanisms in the production of Duroziez's sign. *JAMA.* 1933;100:173-177.
- Abbas F, Sapira JD. Mayne's sign is not pathognomonic of aortic insufficiency. *South Med J.* 1987;80:1051-1052.
- L'Abbe KA, Detsky AS, O'Rourke K. Meta-analysis in clinical research. *Ann Intern Med.* 1987;107:224-233.
- Holleman DR, Simel DL. Does the clinical examination predict airflow limitation? *JAMA.* 1995;273:313-319.
- Koopman PAR. Confidence intervals for the ratio of two binomial proportions. *Biometrics.* 1984;40:513-517.
- Centor RM, Keightley J. *The Two by Two Analyzer.* v1.0. 1992.
- Raflerty EB, Holland WW. Examination of the heart. *Am J Epidemiol.* 1967;85:438-444.
- Sharma RS. Measurement of intensity of heart sounds and murmurs. *Lancet.* 1981;2:612.
- Dubrow RJ, Calatayud JB, Abraham S, Caceres CA. A study of physician variation in heart-sound interpretation. *Med Ann Dist Columbia.* 1964;33:305-308, 355.
- Mangione S, Nieman LZ. Cardiac auscultatory skills of internal medicine and family practice trainees. *JAMA.* 1997;278:717-722.
- St Clair EW, Oddone EZ, Waugh RA, Corey GR, Feussner JR. Assessing housestaff diagnostic skills using a cardiology patient simulator. *Ann Intern Med.* 1992;117:751-756.
- Aronow WS, Kronzon I. Correlation of prevalence and severity of aortic regurgitation detected by pulsed doppler echocardiography with the murmur of aortic regurgitation in elderly patients in a long-term health care facility. *Am J Cardiol.* 1989;63:128-129.
- Grayburn PA, Smith MD, Handshoe R, Friedman BJ, DeMarie AN. Detection of aortic insufficiency by standard echocardiography, pulsed doppler echocardiography, and auscultation. *Ann Intern Med.* 1986;104:599-605.
- Roldan CA, Shively BK, Crawford MH. Value of the cardiovascular physical examination for detecting valvular heart disease in asymptomatic subjects. *Am J Cardiol.* 1996;77:1327-1331.
- Rahko PS. Prevalence of regurgitant murmurs in patients with valvular regurgitation detected by doppler echocardiography. *Ann Intern Med.* 1989;111:466-472.
- Cohn LH, Mason DT, Ross J, Morrow AG, Braunwald E. Preoperative assessment of aortic regurgitation in patients with mitral valve disease. *Am J Cardiol.* 1967;19:177-182.
- Meyers DG, Sagar KB, Ingram RF, Paulsen WJH, Romhilt DW. Diagnosis of aortic insufficiency. *South Med J.* 1982;75:1192-1194.
- Dittmann H, Karsch KR, Seipel L. Diagnosis and quantification of aortic regurgitation by pulsed doppler echocardiography in patients with mitral valve disease. *Eur Heart J.* 1987;8(suppl C):53-57.
- Meyers DG, Olson TS, Hansen DA. Auscultation, M-mode echocardiography and pulsed doppler echocardiography compared with angiography for diagnosis of chronic aortic regurgitation. *Am J Cardiol.* 1985;56:811-812.
- Linhart JW. Aortic regurgitation. *Ann Thorac Surg.* 1971;11:27-37.
- Come PC, Riley MF, Carl LV, Nakao S. Pulsed doppler echocardiographic evaluation of valvular regurgitation in patients with mitral valve prolapse. *J Am Coll Cardiol.* 1986;8:1355-1364.
- Nienaber CA, von Kodolitsch Y, Nicolas V, et al. The diagnosis of thoracic aortic dissection by noninvasive imaging procedures. *N Engl J Med.* 1993;328:1-9.
- Ward JM, Baker CW, Rubenstein SA, Johnston SL. Detection of aortic insufficiency by pulse doppler echocardiography. *J Clin Ultrasound.* 1977;5:5-10.
- Esper RJ. Detection of mild aortic regurgitation by range-gated pulsed doppler echocardiography. *Am J Cardiol.* 1982;50:1037-1043.
- Saal AK, Gross BW, Franklin DW, Pearlman AS. Noninvasive detection of aortic insufficiency in patients with mitral stenosis by pulsed doppler echocardiography. *J Am Coll Cardiol.* 1985;5:176-181.
- Desjardins VA, Enriquez-Sarano M, Tajik AJ, Bailey KR, Seward JB. Intensity of murmurs correlates with severity of valvular regurgitation. *Am J Med.* 1996;100:149-156.
- Lee D, Chen CH, Hsu TL, Chiang CE, Wang SP, Chang MS. Reappraisal of cardiac murmurs related to aortic regurgitation. *Chin Med J (Engl).* 1995;56:152.
- Aronow WS, Schwartz KS, Koenigsberg M. Correlation of murmurs of mitral stenosis and mitral regurgitation with presence or absence of mitral annular calcium in person older than 62 years in a long-term health care facility. *Am J Cardiol.* 1987;59:181-182.
- Alexander WD, Polak A. Early diastolic murmurs in end-stage renal failure. *Br Heart J.* 1977;39:900.
- Perez JE, Smith CA, Meltzer VN. Pulmonic valve insufficiency. *Ann Intern Med.* 1985;103:497-502.
- Lindroos M, Kupari M, Heikkilä J, Tilvis R. Prevalence of aortic valve abnormalities in the elderly. *J Am Coll Cardiol.* 1993;21:1220-1225.
- Bethel CS. Heart sounds in the aged. *Am J Cardiol.* 1963;11:763-767.